A Radiologist's Perspective on the Importance of Marking Moles in Mammography

blog.beekley.com/a-radiologists-perspective-on-the-importance-of-marking-moles-in-mammography

Friday morning, 8:00 am, my first patient arrives.

A 61 year old woman with a personal history of breast cancer and a mother with postmenopausal breast cancer presents for her annual mammogram.

The routine images are obtained and the patient quietly waits in the dressing room for her results.

Reviewing the images, I see a developing nodular density in the deep subareolar region of the right breast (Images 1, 2, 3, 4).

Image 1. (2017) Right MLO view shows an enlarging, irregular nodular density, along the chest wall.

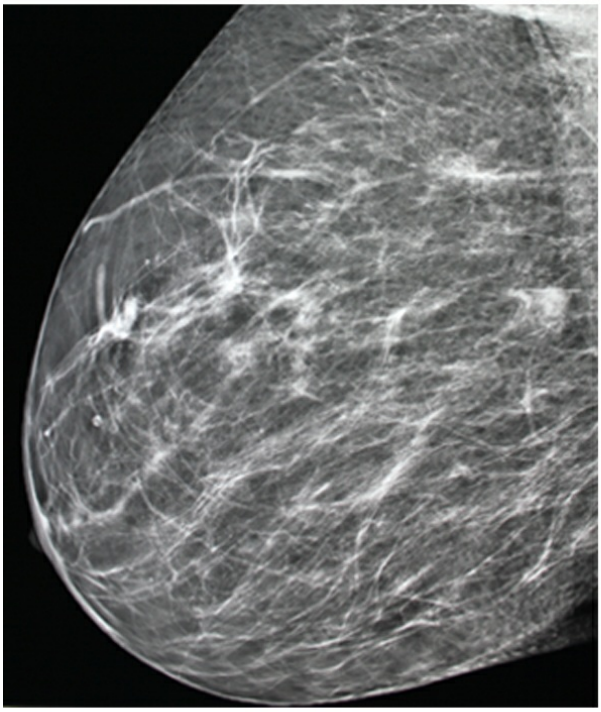

Image 2. (2017) A small arrow marks the nodular density on the MLO view.

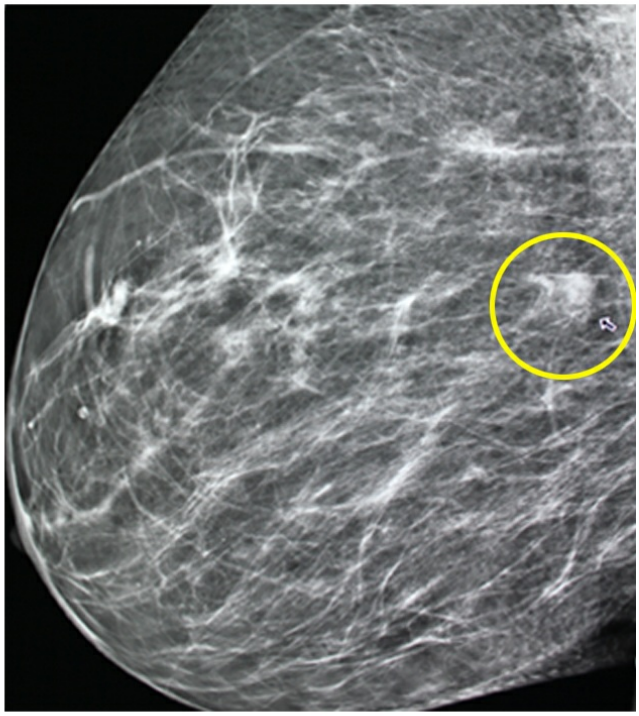

Image 3. (2016) Right MLO view showed a small, stable nodular density deep to the nipple, along the chest wall.

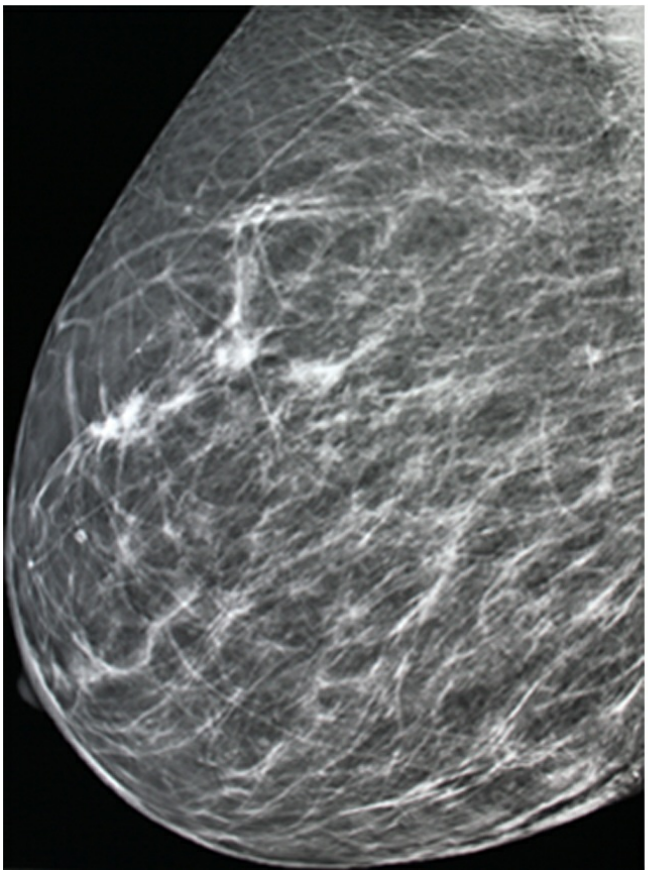

Image 4. (2016) Right CC view showed no abnormality.

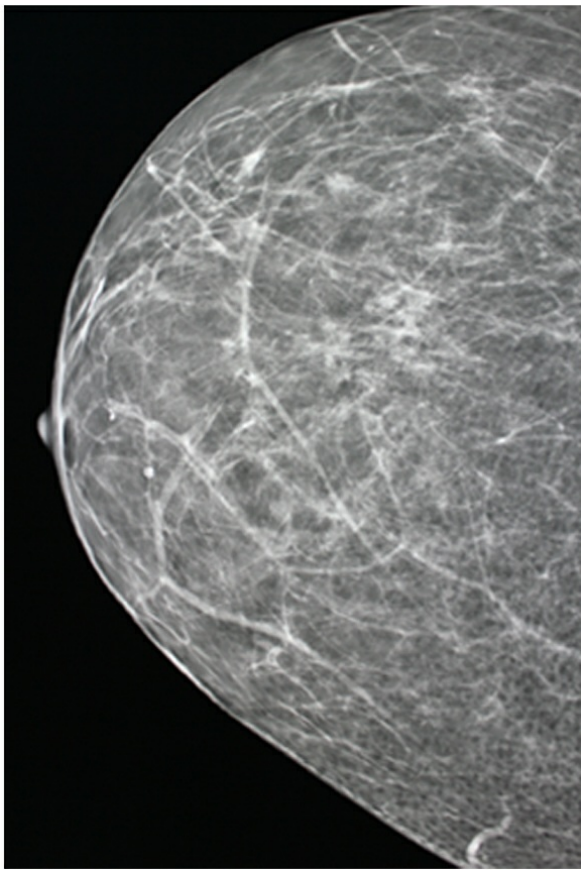

The density has a concerning appearance and I am prepared to perform a limited breast

ultrasound following the additional mammogram images.

My technologist returns to inform me that the patient has a prominent mole in the area and she has marked it for the additional imaging. A marked spot MLO and XCC view were performed.

Thankfully, the developing density corresponds perfectly with the skin lesion (Images 5, 6).

Image 5. Spot MLO view with a mole marker in place confirms the enlarging nodule to be a skin lesion.

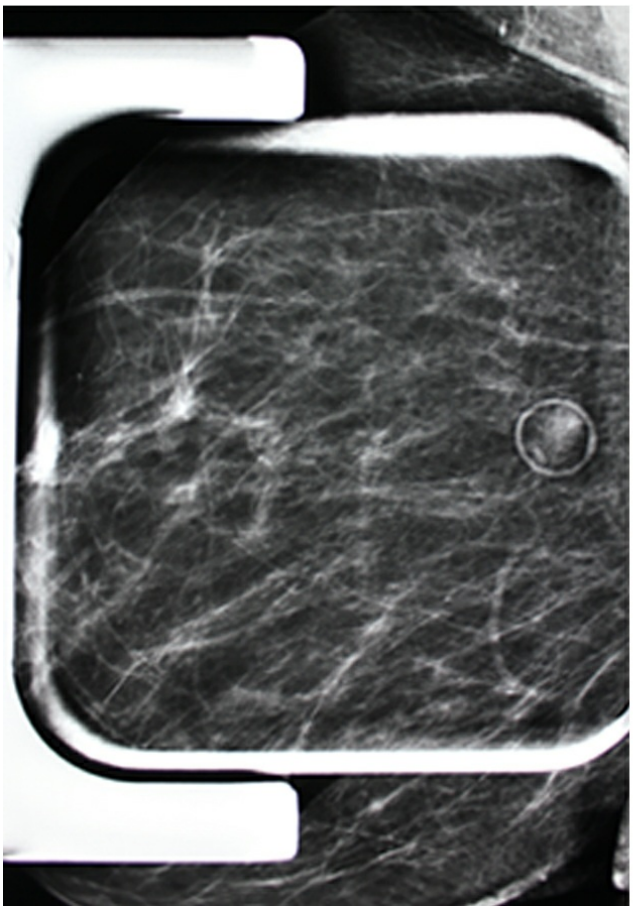

Image 6. Exaggerated CC view with a mole marker in place confirms the mammographic nodular density to be a skin lesion in the outer aspect.

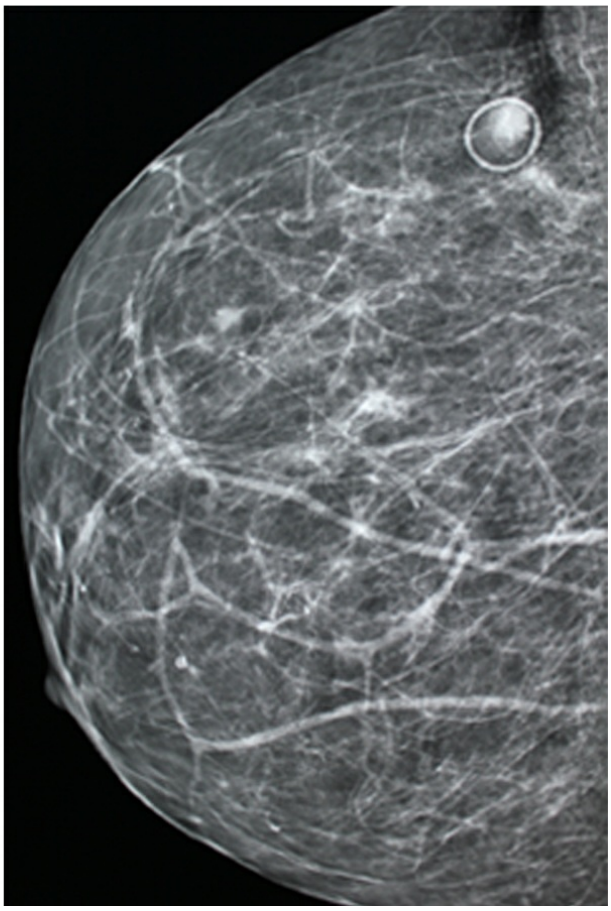

The importance of fully evaluating patients for moles or skin tags is clearly seen in this case.

Without the use of a skin marker, the lesion would have persisted and would not have been visible sonographically. A biopsy recommendation most likely would have followed, given the patient's personal high risk as a breast cancer survivor.

Had the lesion in this patient been marked initially, additional mammograms could have been avoided.

While this patient's images were immediately interpreted, in many situations she would have been called back for additional imaging, markedly raising the patient stress level.

Additionally, identifying the density as a mole, obviated the need for a breast ultrasound. Breast cancer patients tend to have a higher anxiety level than the general population at the time of their mammogram imaging, as they are aware of their increased risk for both recurrence or a new cancer.

With appropriate marking of visible skin lesions, both additional radiation exposure and patient anxiety can be reduced in mammography patients.

Related Articles:

Effective Communication in Mammography is Key to Successful Patient Care

Architectural Distortion in 3D Mammography

New TomoSPOT Skin Markers Help Reduce Risk of False Negatives & Positives in 3D Mammography

Take Control - Mark Those Nipples During Your Mammogram

Julie Gershon, M.D.
Diagnostic Radiologist, J Gershon Breast Imaging